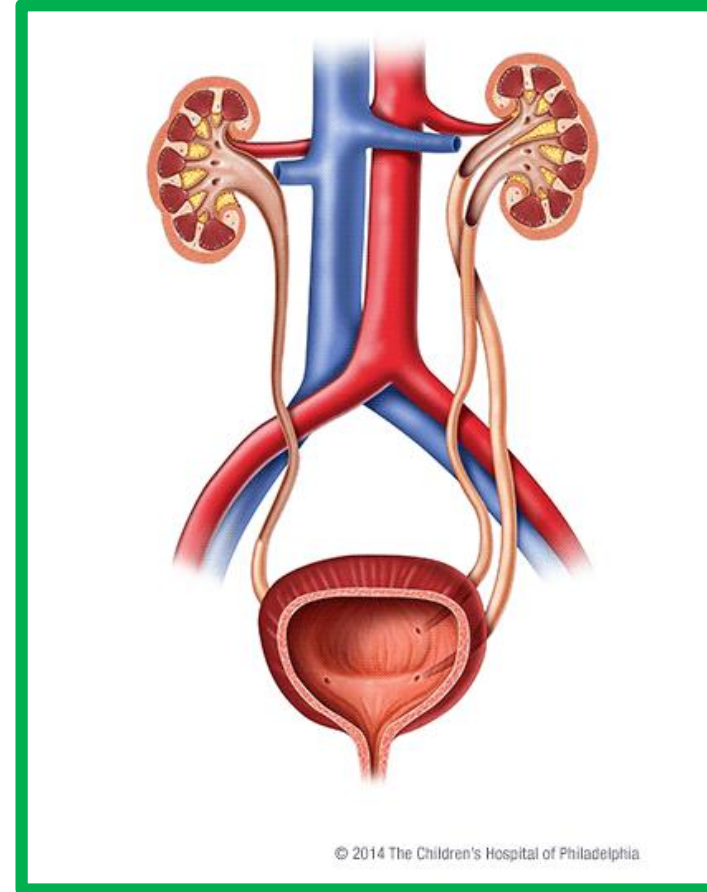
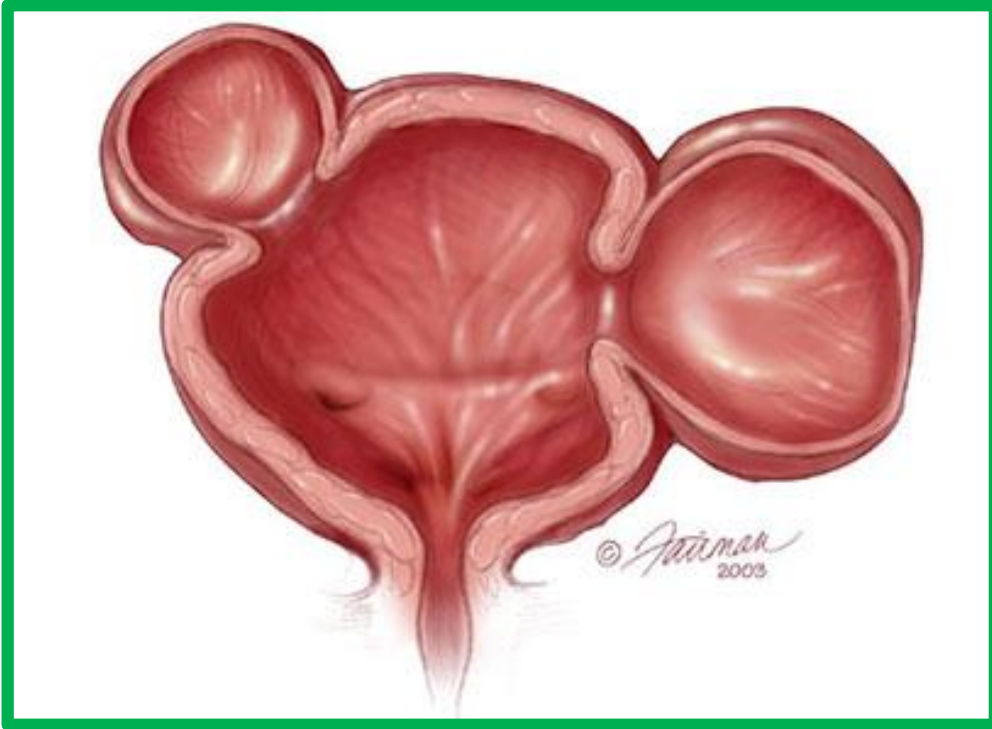


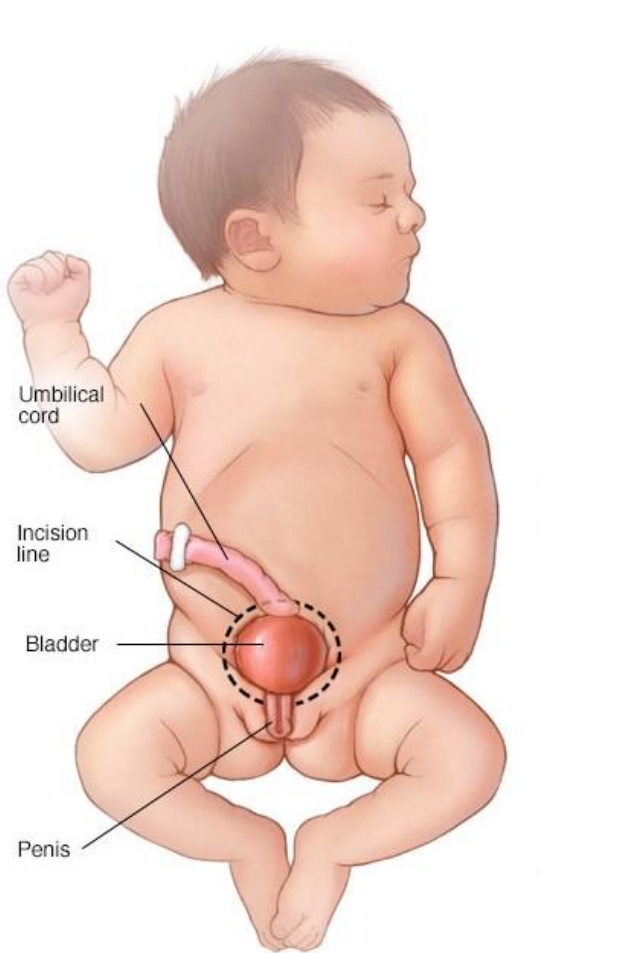
GMT109: Practical Class- Lower Urinary Tract and Male Genital Tract Pathology

Dr. Zaleha Kamaludin
Pathology Department
7.2.2022

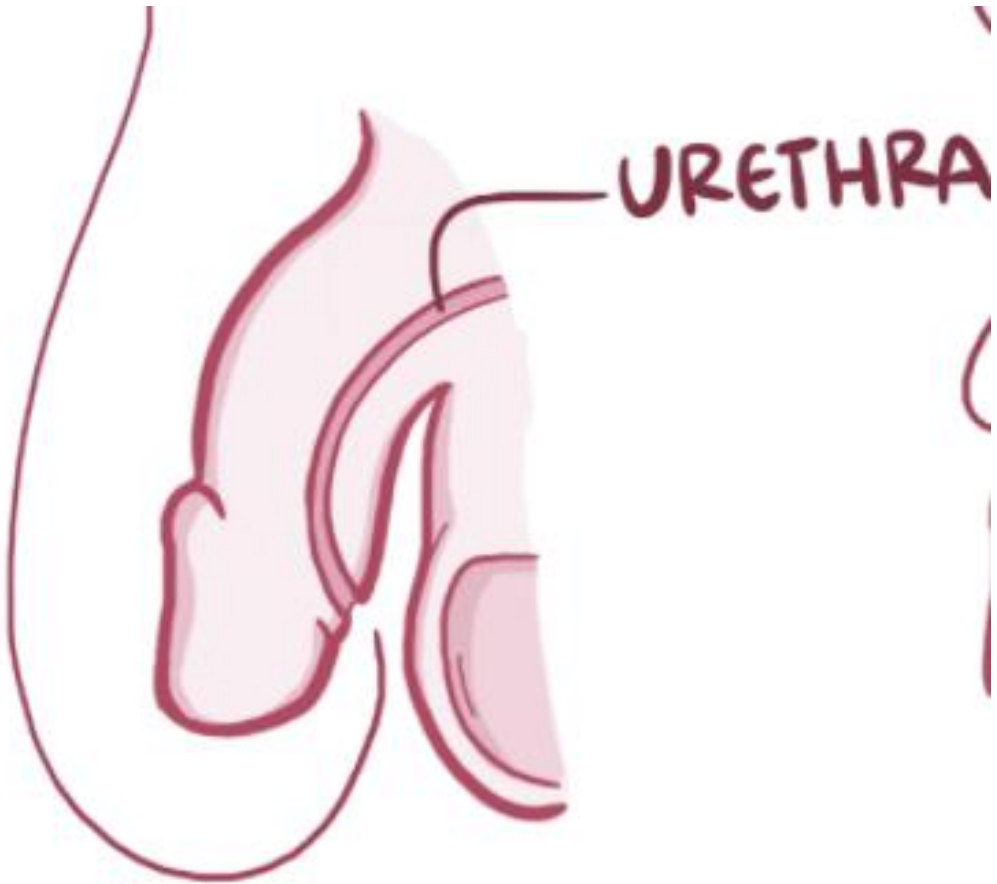

Name the pathology of the picture show below:



Name the pathology of the picture show below:



© MAYO FOUNDATION FOR MEDICAL EDUCATION AND RESEARCH. ALL RIGHTS RESERVED



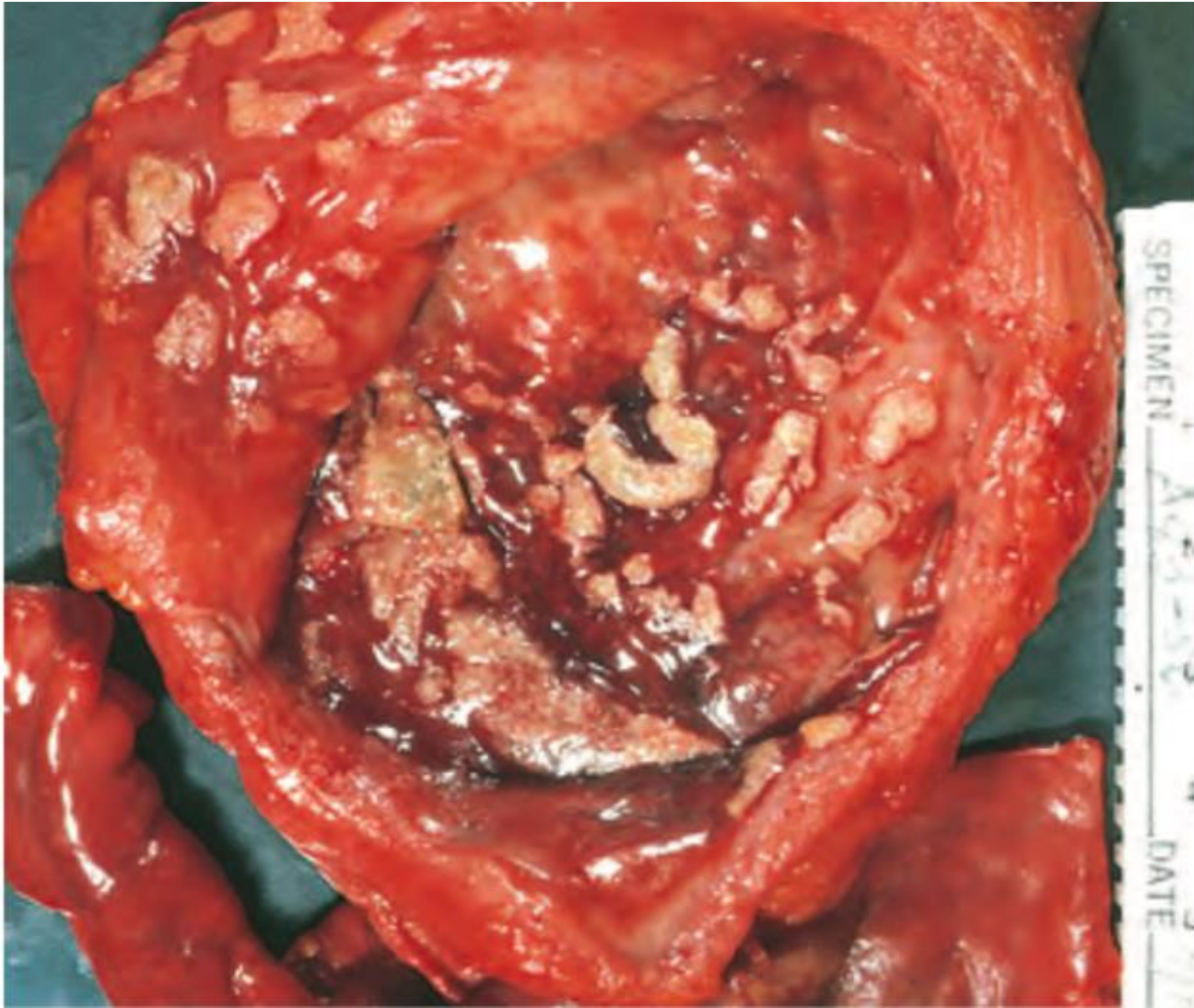
List the causes of ureter obstruction and its complication

What is Vesicoureteral reflux?

What is the causes and its complication

List the causes of acute and chronic cystitis

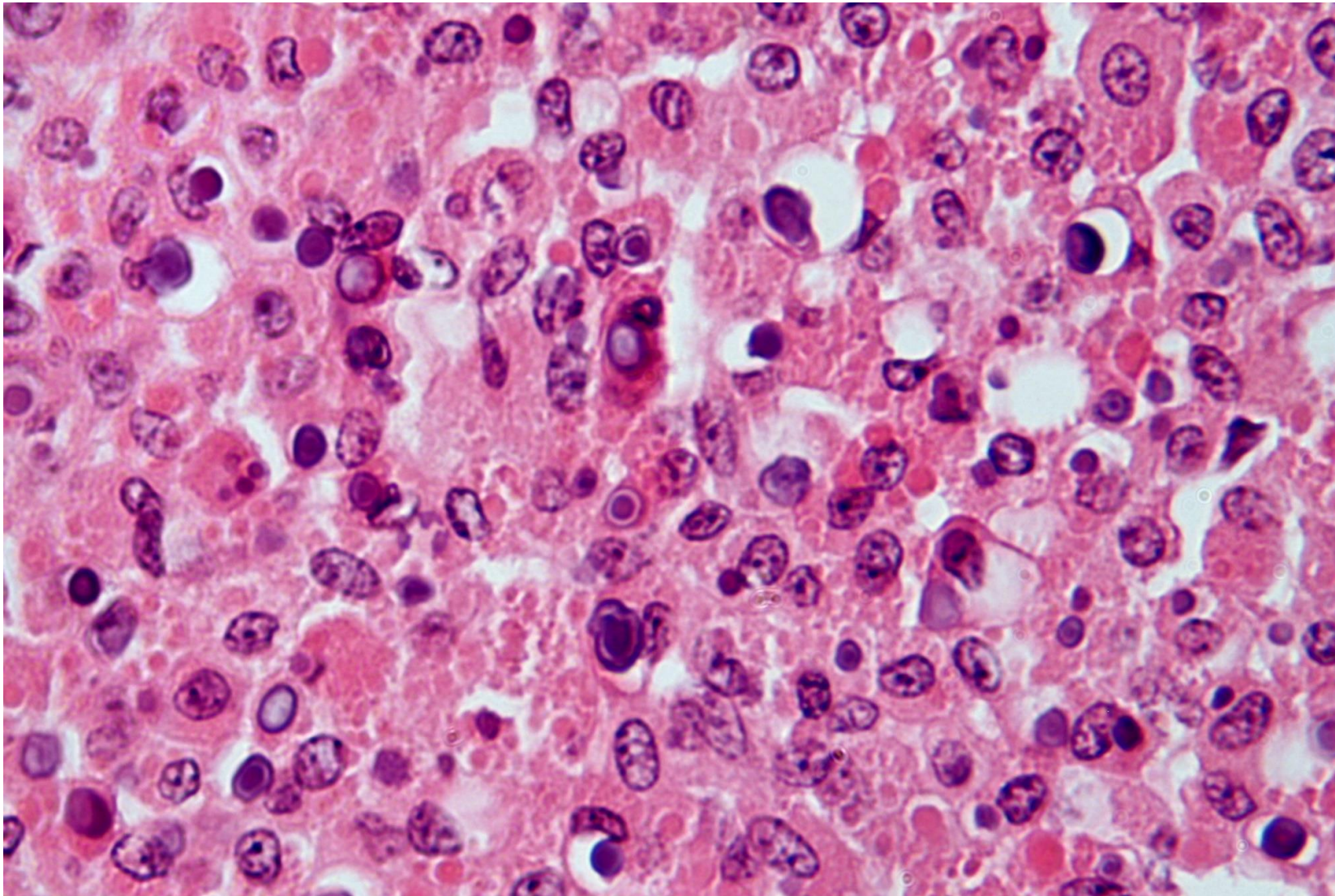
What are the clinical features of cystitis?



Question 1

50-year-old, male, presented with painful hematuria.

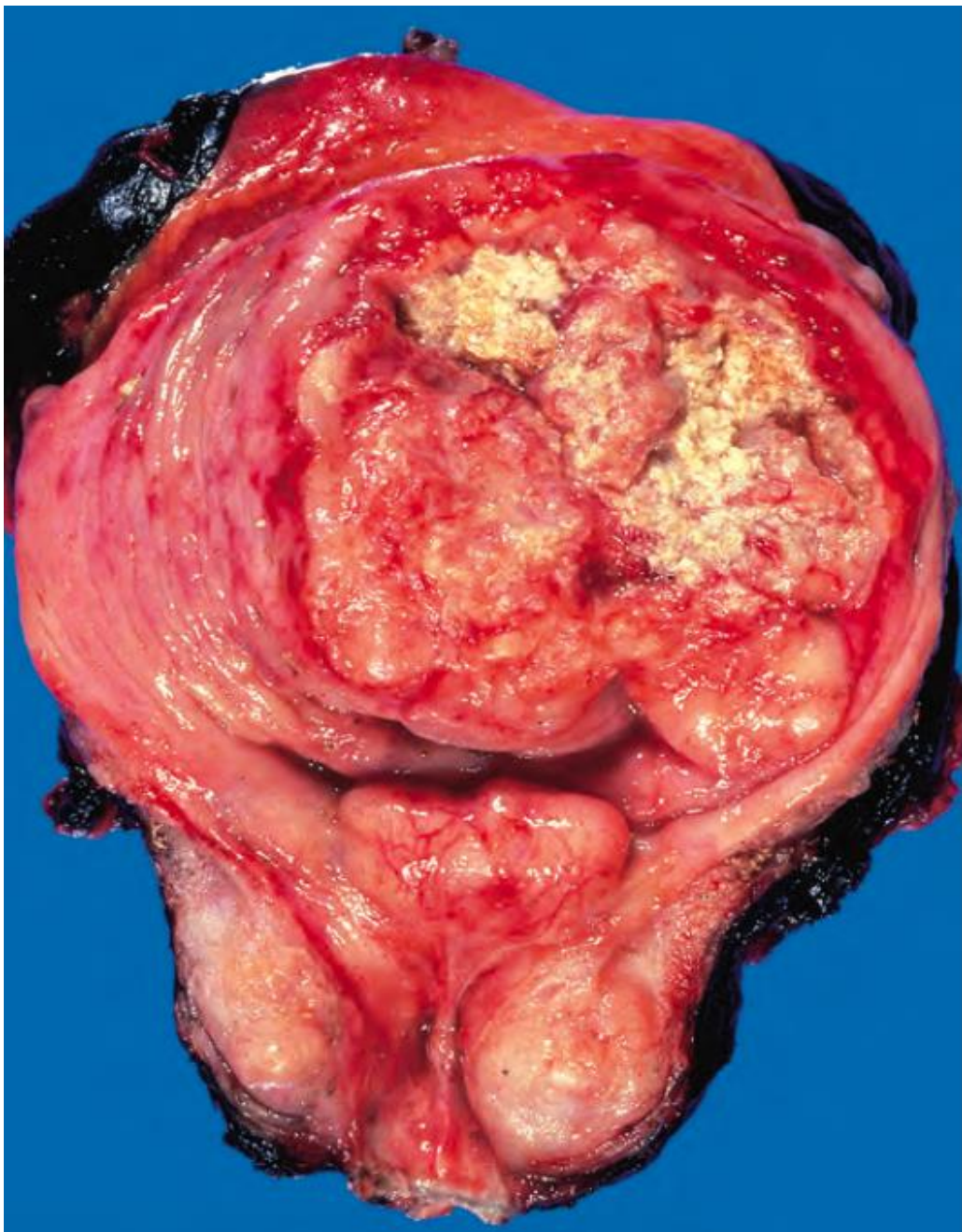
1. Describe the gross morphological features of photomicrograph A1:



photomicrograph A2

2. Describe the histopathological findings in photomicrograph A2 (a section taken from photomicrograph A1)

3. State your diagnosis



photomicrograph A1

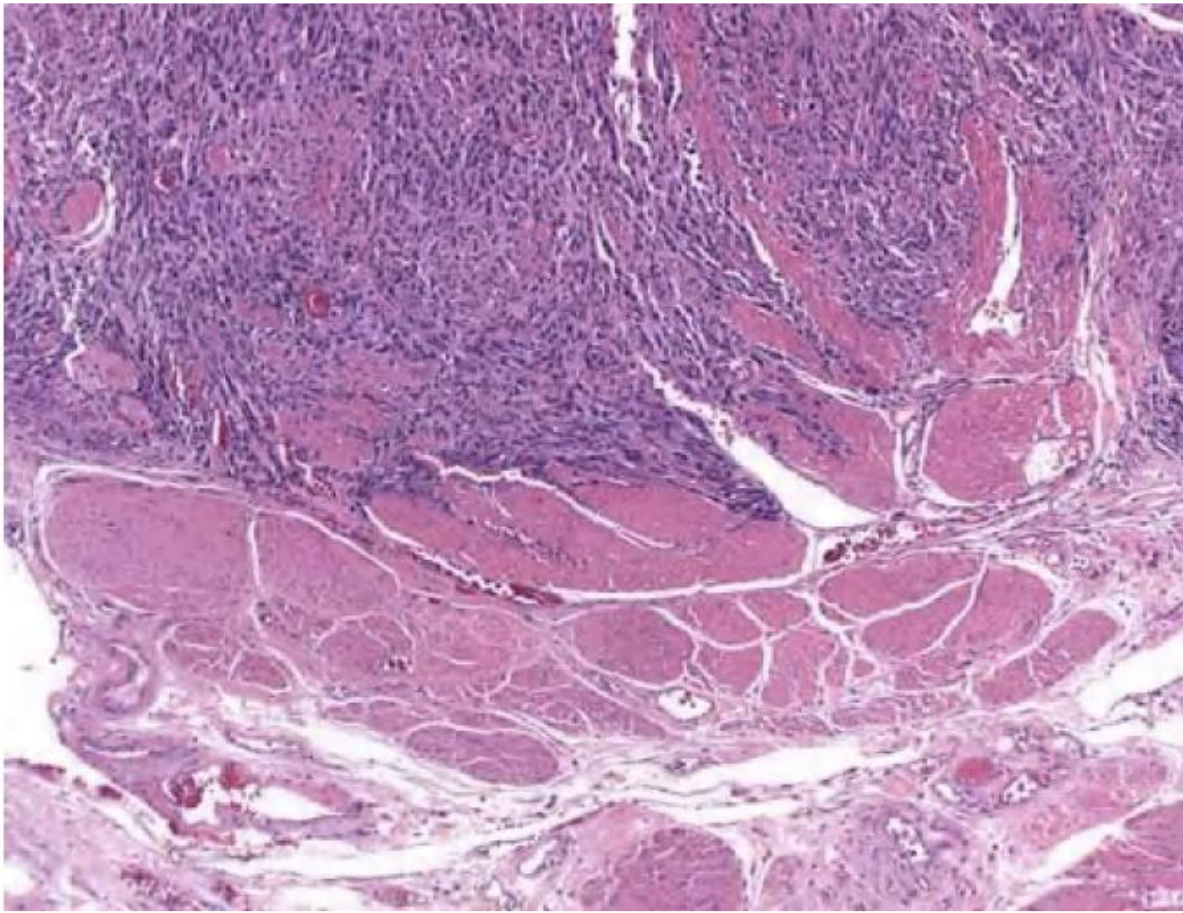
Question 2

60-year-old, male, presented with painless hematuria.

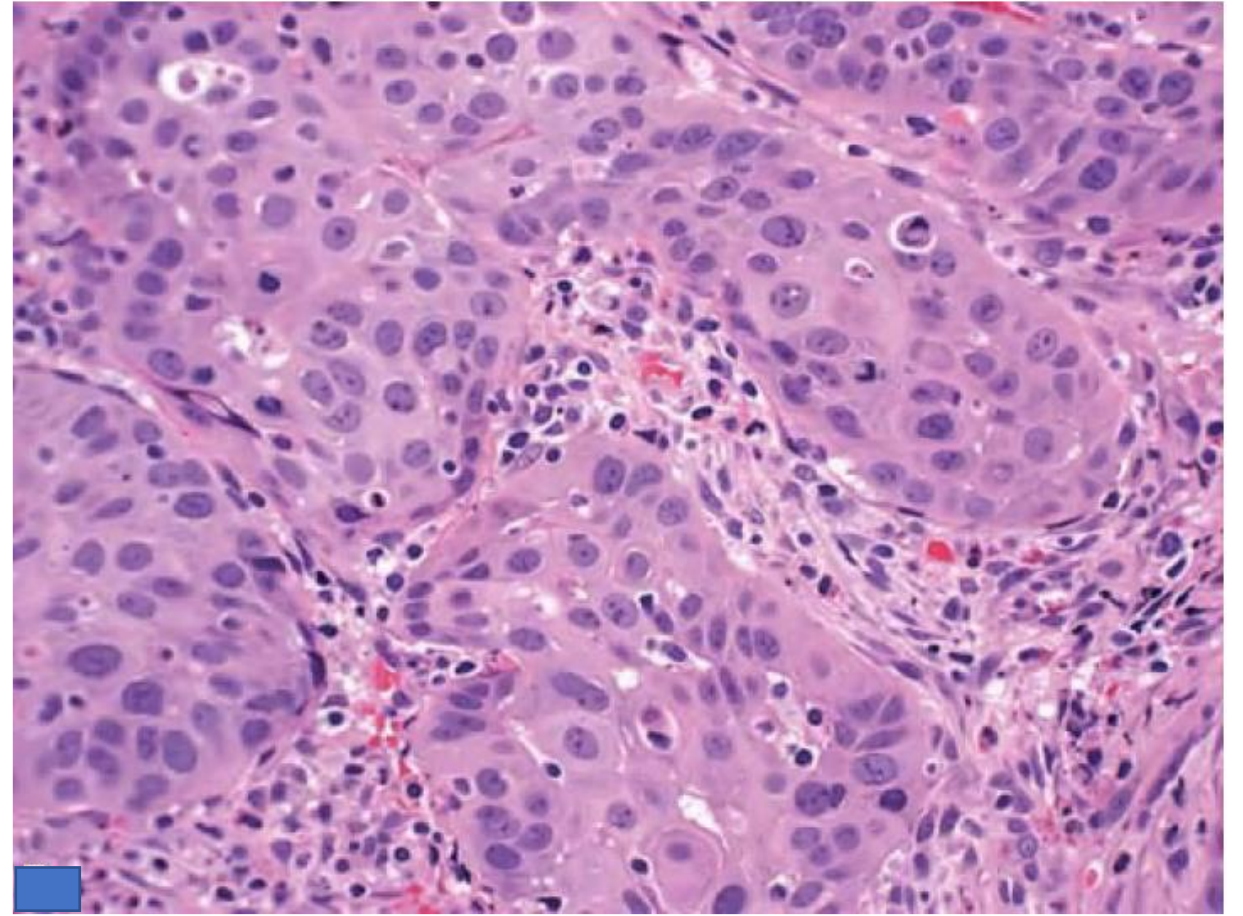
Describe the gross morphological features of photomicrograph A1:

2. Describe the histopathological findings in photomicrograph A2 & A3 (a section taken from photomicrograph A1)

3. State your diagnosis



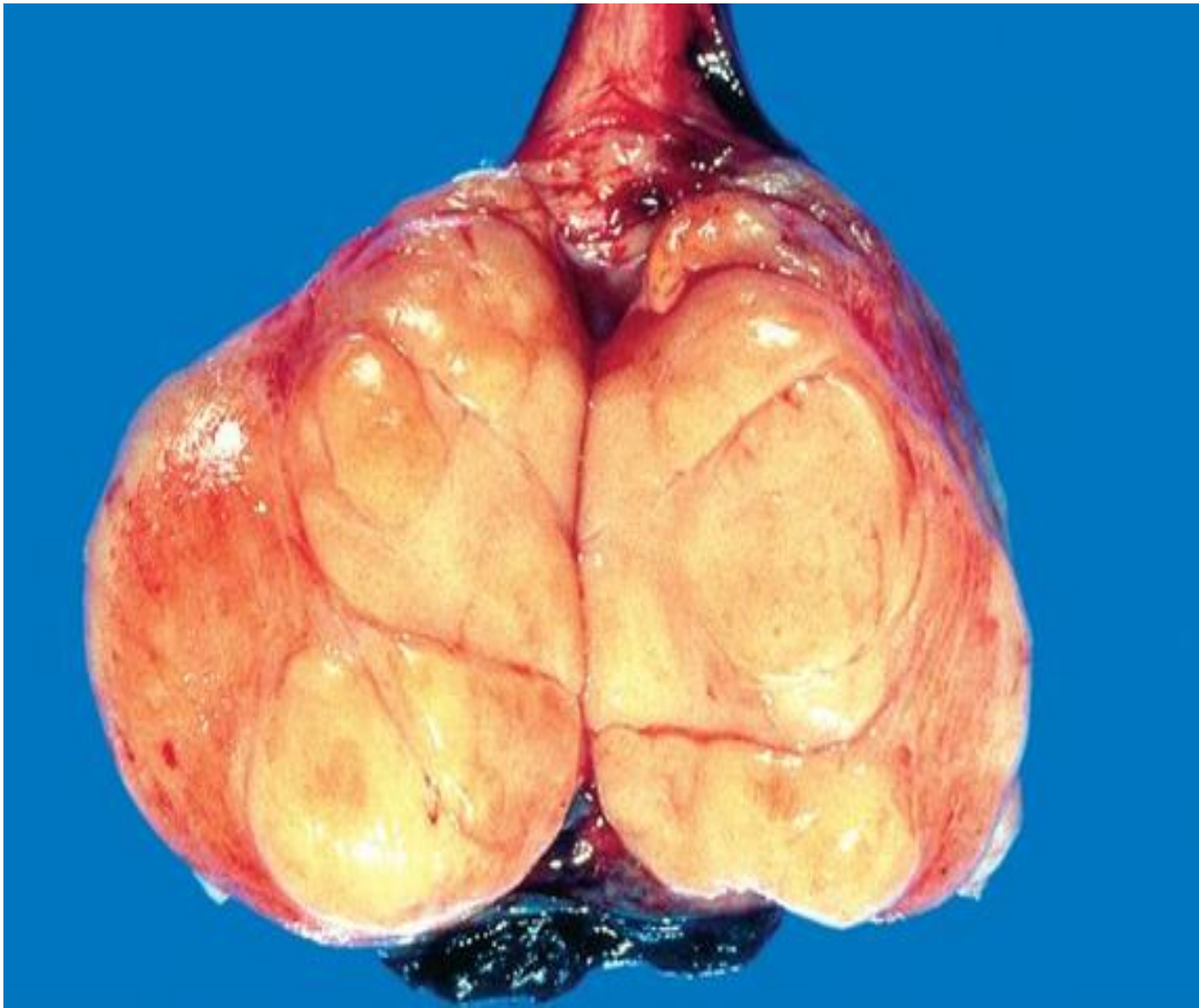photomicrograph A2



photomicrograph A3

Give 5 risk factors that possible to cause bladder carcinoma

Describe the **molecular pathogenesis**
bladder tumour?

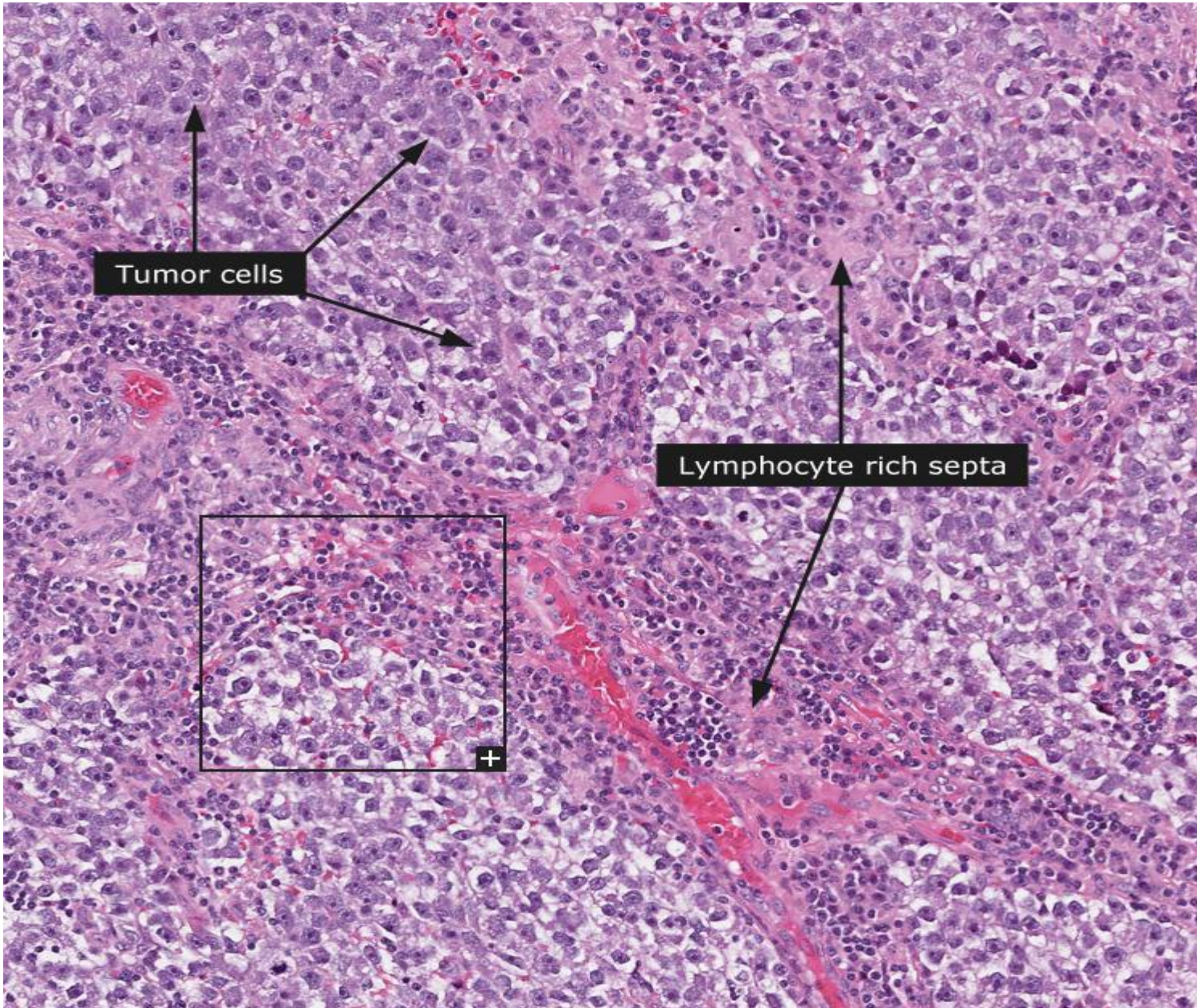


photomicrograph A1

Question 3

18-year-old, male, presented with testicular mass.

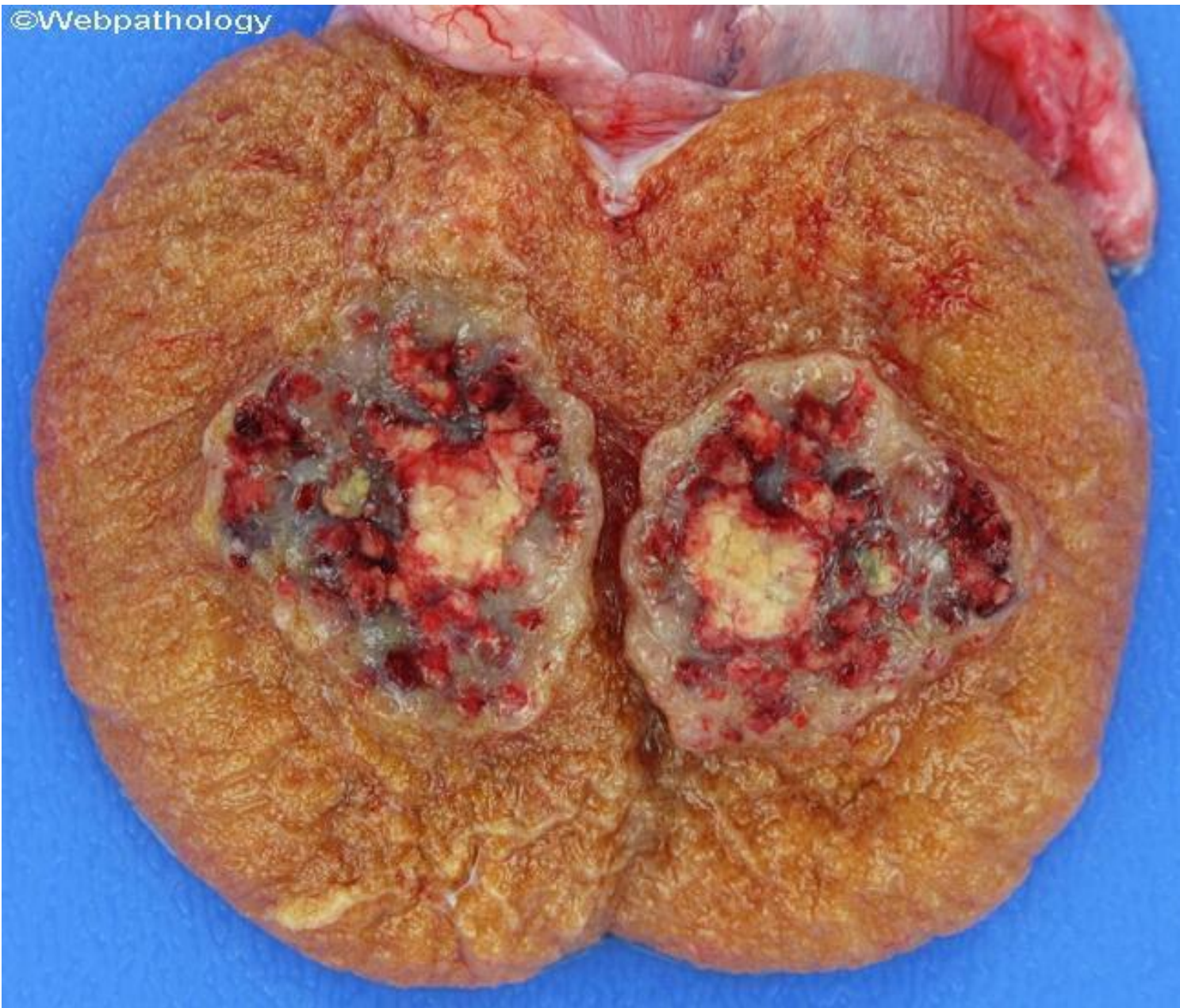1. Describe the gross morphological features of photomicrograph A1



photomicrograph A2

2. Describe the histopathological findings in photomicrograph A2 (a section taken from photomicrograph A1)

3. State your diagnosis

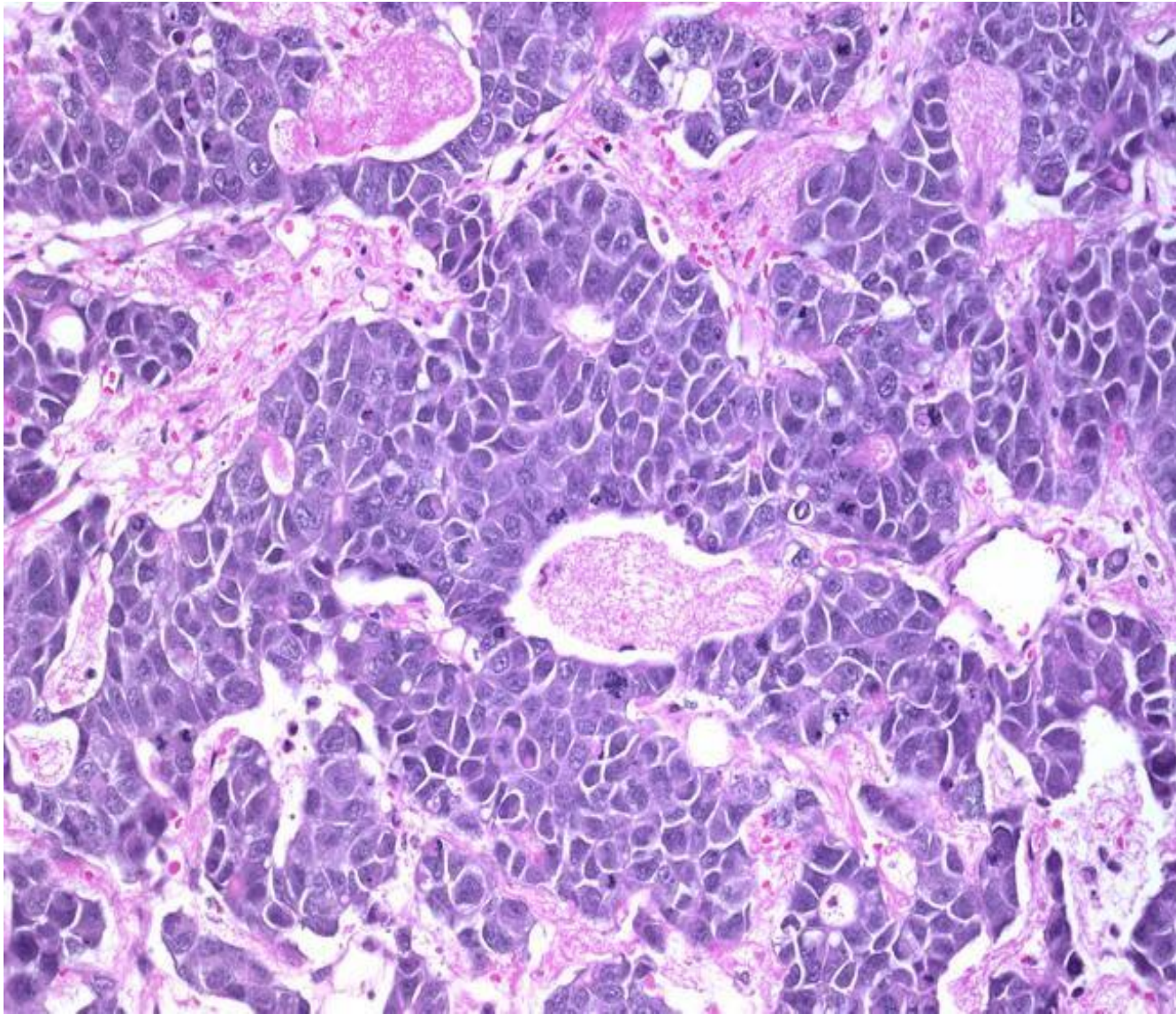


Question 4

22-year-old, male, presented with testicular mass.

Describe the gross morphological features of photomicrograph A1:

photomicrograph A1



2. Describe the histopathological findings in photomicrograph A2 (a section taken from photomacrograph A1)

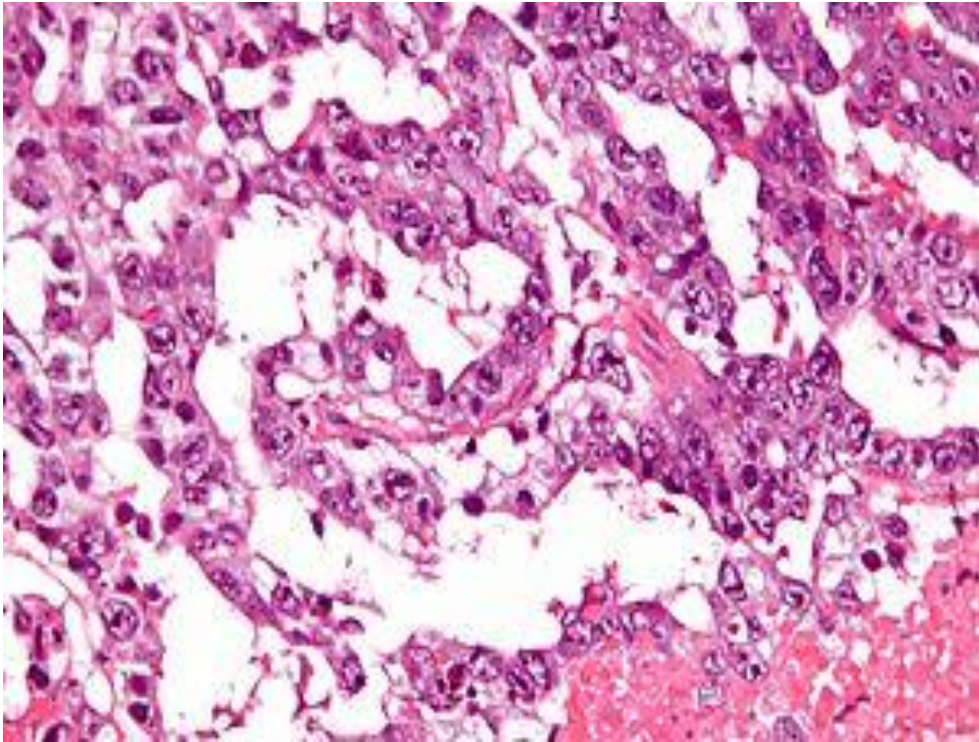
3. State your diagnosis?

Question 5

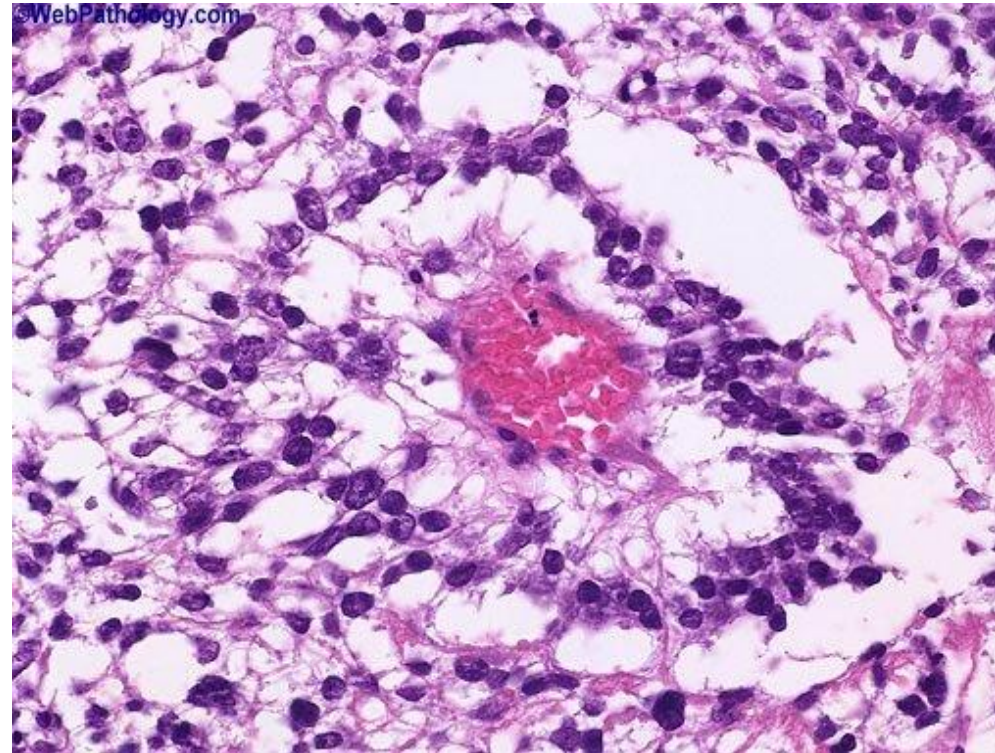
18-year-old, male, presented with testicular mass.

1. Describe the histopathological findings in photomicrograph A1 and A2

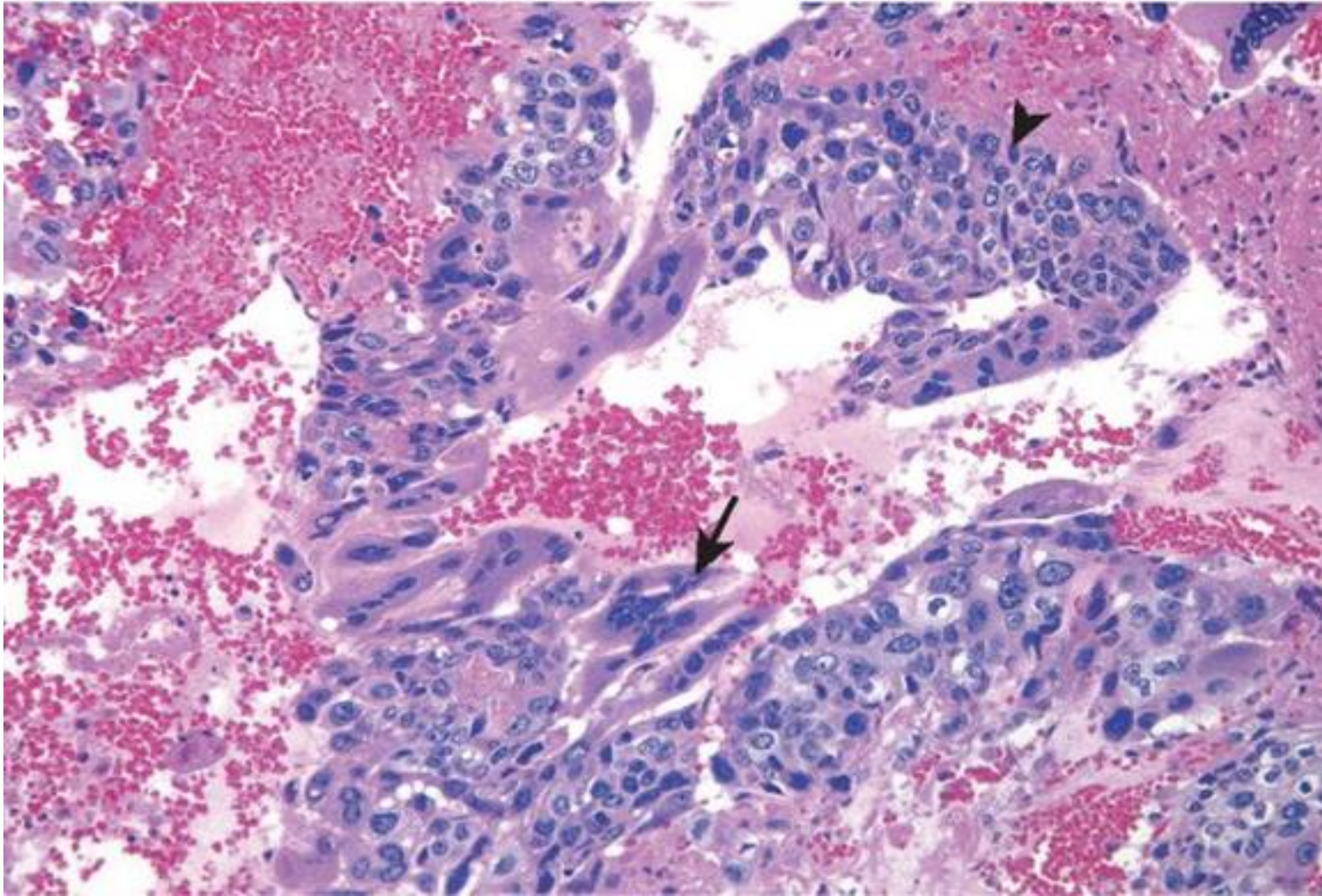
2. State your diagnosis



photomicrograph A1



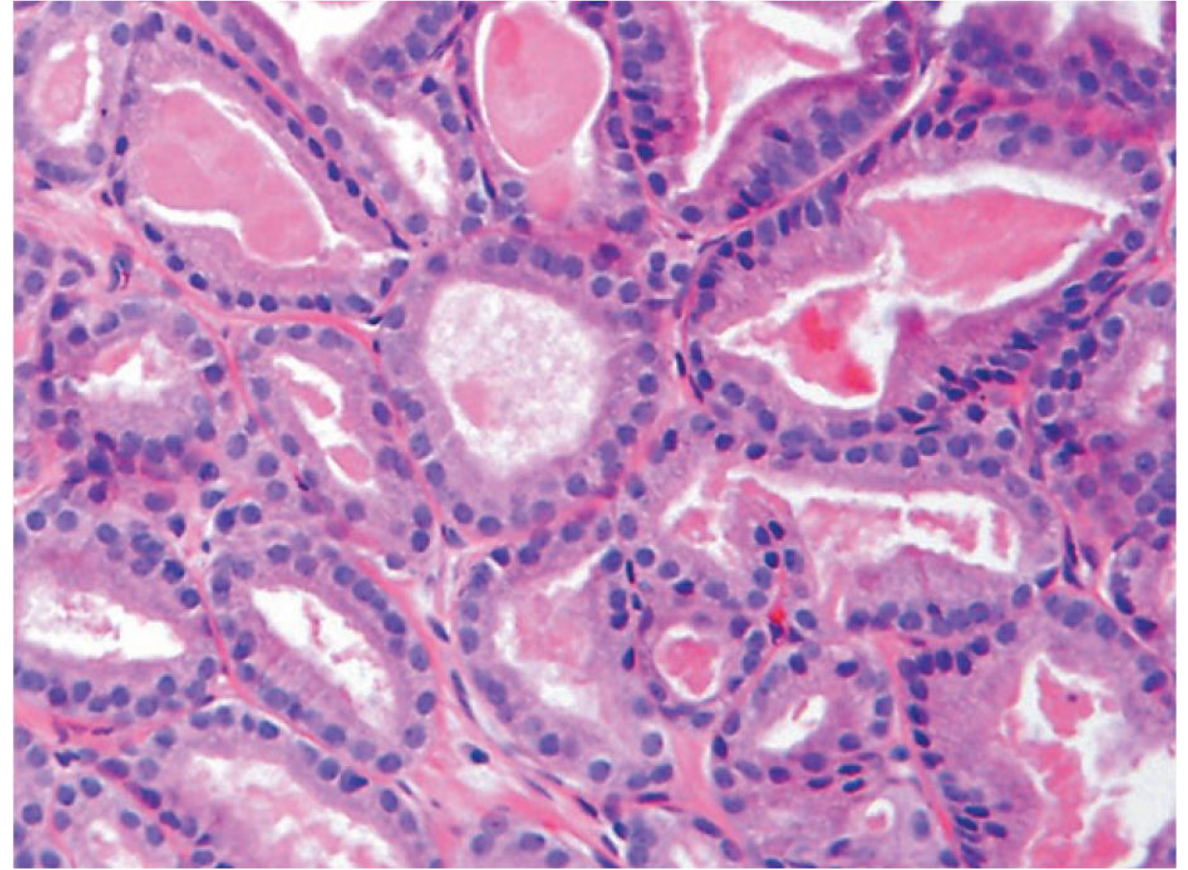
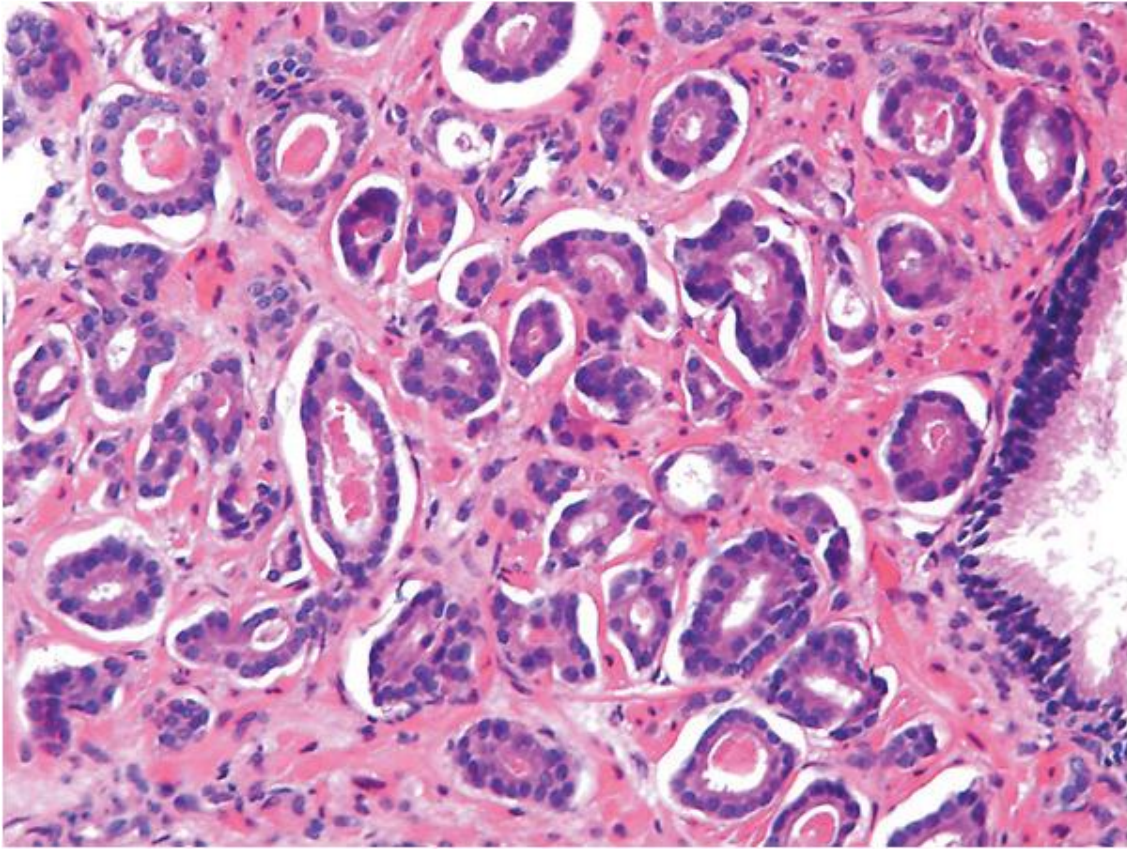
photomicrograph A2



Question 6

20-year-old, male, presented with testicular mass.

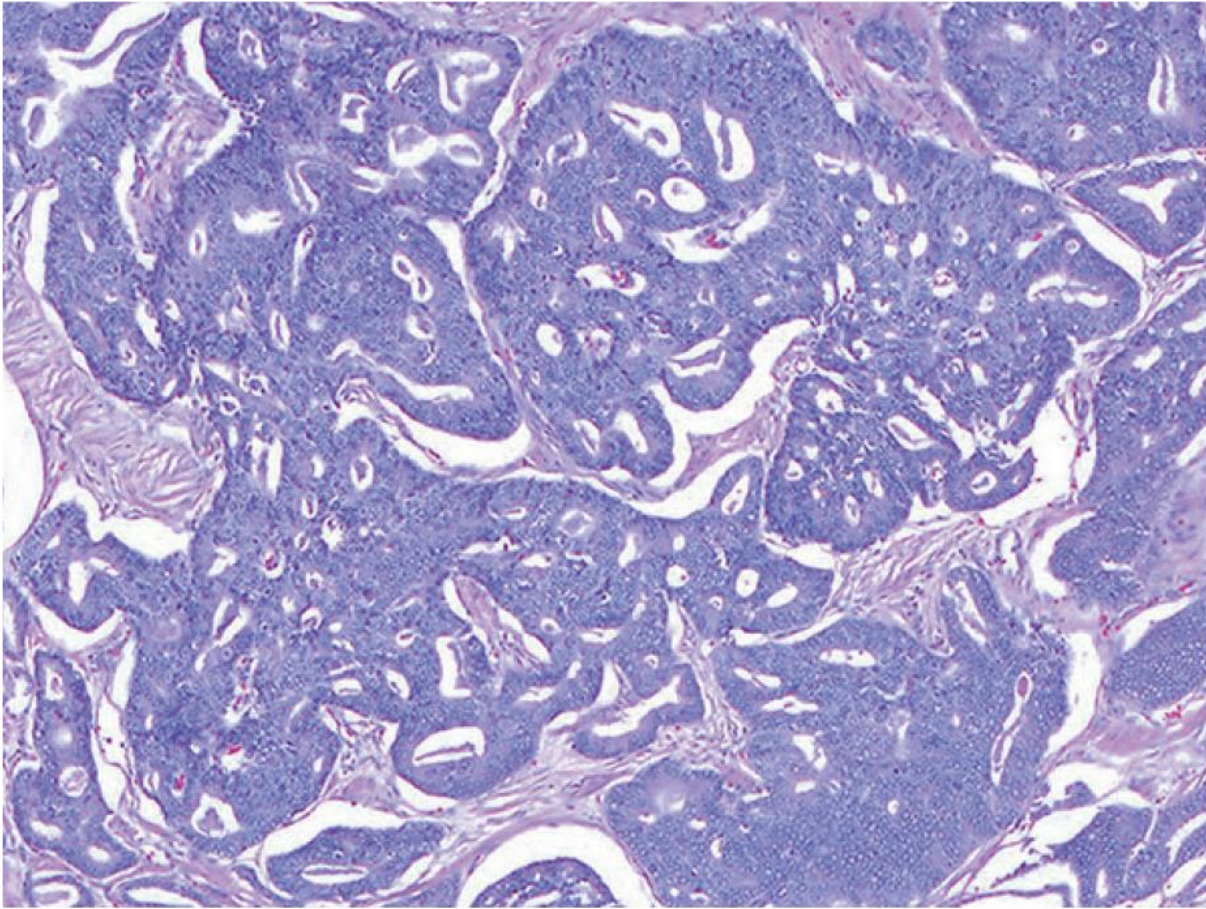
1. Describe the histopathological findings in photomicrograph A1
2. State your diagnosis



Question 7

This 63-year-old man had an elevated PSA and an indurated prostate on rectal examination. Biopsies were taken.

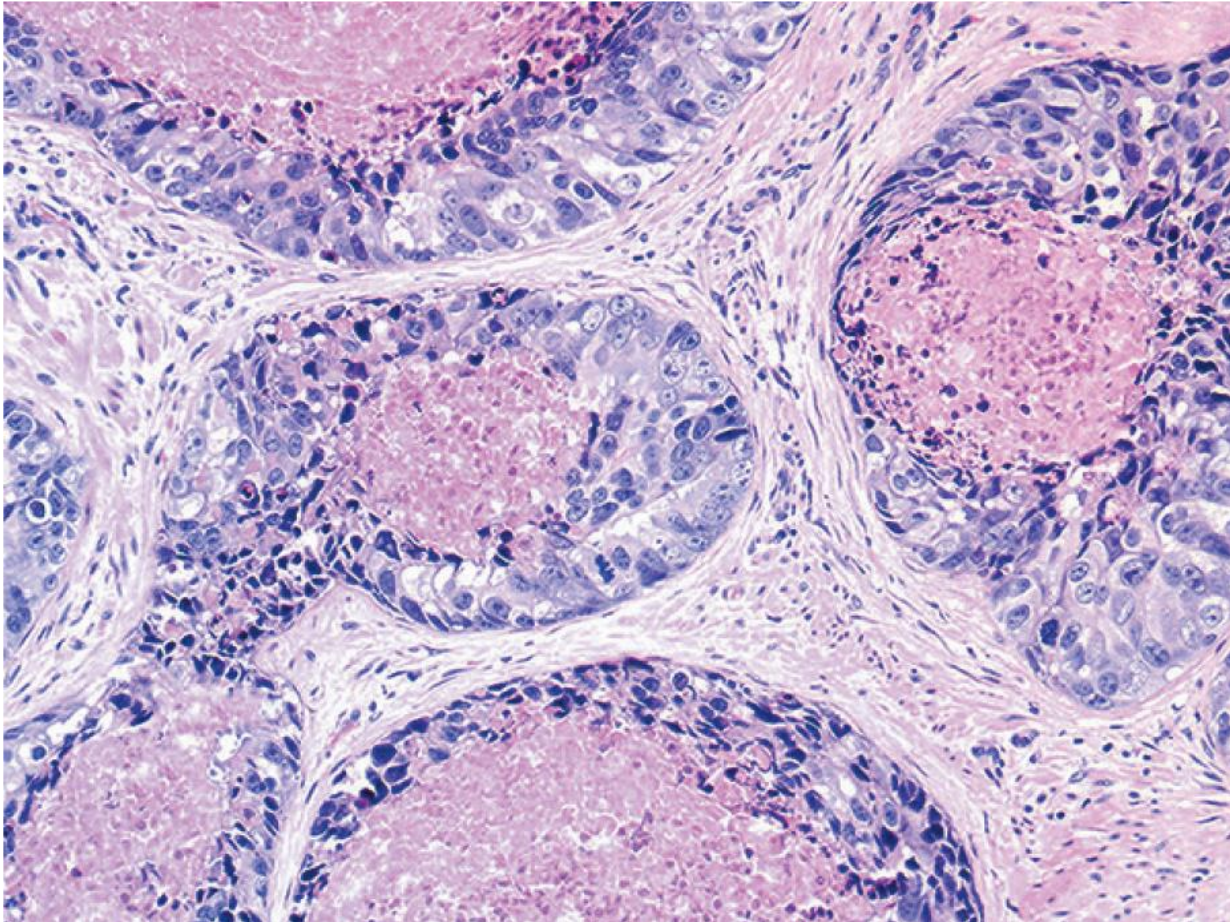
1. Describe the histopathological findings in photomicrograph above
2. What is the diagnosis?



Question 8

This 60-year-old man had an elevated PSA and an indurated prostate on rectal examination. Biopsies were taken.

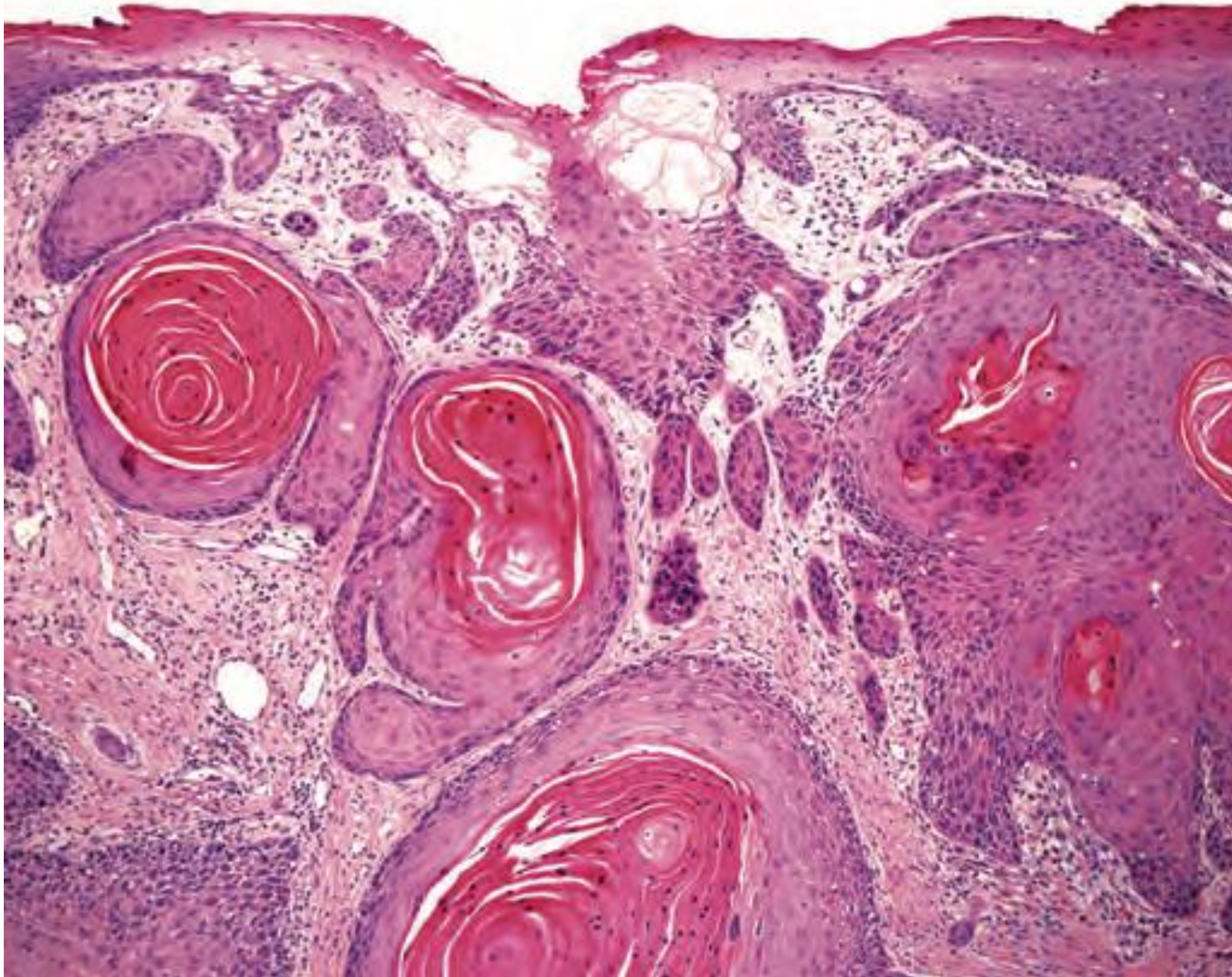
1. Describe the histopathological findings in photomicrograph provided.
2. What is the diagnosis?



Question 9

This 60-year-old man had an elevated PSA and an indurated prostate on rectal examination. Biopsies were taken.

1. Describe the histopathological findings in photomicrograph provided.
2. What is the diagnosis?



Question 10

A 57-year-old male with case of difficulty in voiding urine and penile pain. Biopsies were taken.

1. Describe the histopathological findings in photomicrograph provided.
2. What is the diagnosis?